

VIDEOS IN CLINICAL MEDICINE

Ankle–Brachial Index for Assessment of Peripheral Arterial Disease

S. Marlene Grenon, M.D.C.M., Joel Gagnon, M.D., and York Hsiang, M.D.

OVERVIEW

The ankle–brachial index is used in the evaluation of patients for peripheral arterial disease. The initial examination of such patients usually includes palpation of peripheral pulses. However, because there is inconsistency in the ability of practitioners to palpate pedal pulses, this method can be unreliable. Occasionally, it may not be possible to palpate pedal pulses in a healthy patient — for example, when there is a congenital absence of the dorsalis pedis or posterior tibial pulses, which occurs in 10% of the population.^{1,2}

INDICATIONS

Although other methods exist to assess the peripheral vasculature more objectively, the ankle–brachial index represents a simple, reliable method for diagnosing peripheral arterial disease. More specific indications include evaluation of leg pain, evaluation for ischemia of the legs (symptoms of claudication, pain at rest, and the presence of foot ulcers or gangrene), screening for atherosclerosis, and evaluation of vascular compromise in patients with trauma of the lower legs.³ Measurement of the ankle–brachial index may also be useful in determining the prognosis for patients with diffuse vascular disease and for evaluating the success of interventional or surgical procedures, such as angioplasty, stenting, or lower-extremity bypass surgery.

CONTRAINDICATIONS

The few contraindications for the measurement of the ankle–brachial index include excruciating pain in the patient's legs or feet and the presence of deep venous thrombosis, which could lead to thrombus dislodgment. In a patient with suspected deep venous thrombosis, it would be prudent to perform a duplex ultrasound study to exclude this possibility before measuring the ankle–brachial index. Although the readings may be altered when vessels are calcified or incompressible (such as in elderly patients, patients with diabetes, or patients with end-stage renal failure requiring dialysis), these conditions are not absolute contraindications to measuring the ankle–brachial index.

EQUIPMENT AND PREPARATION

To measure an ankle–brachial index, you will need the following equipment: a continuous-wave Doppler machine, ultrasonic gel, and a sphygmomanometer with a blood-pressure cuff (Fig. 1). To examine peripheral blood vessels, you will need a Doppler ultrasound probe with a frequency of 8 to 9 MHz. A handheld Doppler probe is usually adequate to measure the ankle–brachial index. The width of the

From the Department of Vascular Surgery, Vancouver General Hospital, University of British Columbia, Vancouver, BC, Canada.

N Engl J Med 2009;361:e40.

Copyright © 2009 Massachusetts Medical Society.

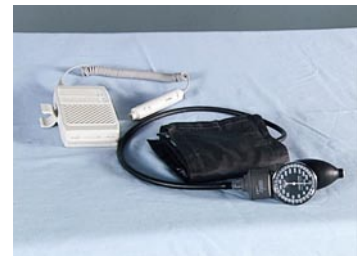

Figure 1. Equipment Used in the Measurement of an Ankle–Brachial Index.

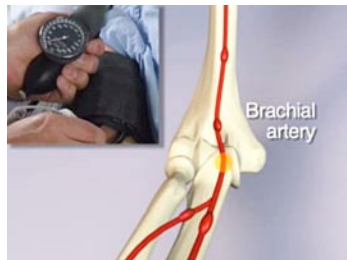


Figure 2. Measurement of Blood Pressure in the Arm.

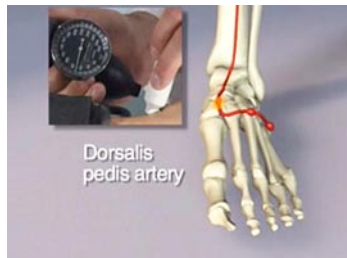

Figure 3. Measurement of the Systolic Pressure in the Dorsalis Pedis Artery.

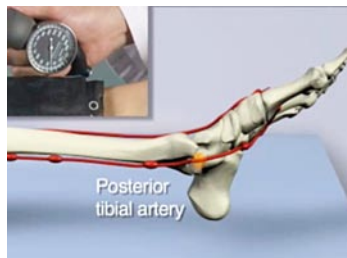


Figure 4. Measurement of the Systolic Pressure in the Posterior Tibial Artery.

bladder for the blood-pressure cuff should be 20% larger than the diameter of the limb to be measured — put another way, the bladder should correspond to 40% of the limb circumference.⁴ The patient should be examined in a supine position and in a warm environment to improve the patient's comfort and to ensure the accuracy of the examination.

PROCEDURE AND CALCULATION

Place the blood-pressure cuff on the patient's right or left arm (Fig. 2). Palpate the brachial pulse. Apply gel at the site where you feel the pulse, and obtain a Doppler signal by placing the probe at a 60-degree angle toward the patient's head. Inflate the cuff rapidly to 20 to 30 mm Hg above the point of cessation of brachial-artery flow, then slowly deflate the blood-pressure cuff in order to note the systolic value. Wipe the gel from the patient's skin and repeat the procedure on the other arm.

After measuring the systolic blood pressure in the arms, place the cuff just above the ankle on the right or left leg. The anatomical landmark of the dorsalis pedis artery should be lateral to the extensor hallucis longus tendon (Fig. 3). Place the Doppler probe on the palpable dorsalis pedis pulse or on the site that produces the best arterial Doppler signal from the dorsalis pedis artery. Once again, inflate the blood-pressure cuff to 20 to 30 mm Hg above the level at which flow ceases, then deflate the cuff slowly and note the systolic pressure (the pressure at which you first hear the flow from the dorsalis pedis artery). Repeat the procedure for the posterior tibial artery (Fig. 4). Then repeat the procedure for the contralateral leg to obtain the systolic pressure from both the dorsalis pedis and posterior tibial arteries.

To calculate the ankle-brachial index, divide the systolic blood pressure in the ankle by the systolic blood pressure in the arm. The higher brachial systolic pressure is usually chosen for calculation, simply because the vessels of an arm may be affected by arterial occlusive disease. The higher of the systolic pressures from the dorsalis pedis or posterior tibial artery is used to determine the ankle-brachial index.

INTERPRETATION

With a patient at rest, a normal ankle-brachial index ranges from 0.91 to 1.30. A reading above 1.30 is usually suggestive of incompressible tibial arteries. Decreases in the ankle-brachial index are consistent with peripheral arterial disease. Mild-to-moderate peripheral arterial disease usually produces an ankle-brachial index in the range of 0.41 to 0.90. A reading below 0.40 suggests the presence of severe peripheral arterial disease^{5,6} (see guidelines^{7,8}). Depending on the patient's presentation and symptoms, further investigations may be required, including the use of computed tomography, catheter angiography, magnetic resonance imaging, or duplex ultrasound imaging.⁵

LIMITATIONS

Use of the ankle-brachial index does have limitations. These include inaccurate measurements as a result of calcified or incompressible vessels (which would produce falsely elevated readings) and the presence of a subclavian-artery stenosis (which could also falsely elevate the ankle-brachial index on the side of the stenosis). A difference of more than 10 mm Hg between the two arm pressures suggests the presence of a subclavian-artery stenosis.

CONCLUSIONS

Measurement of the ankle-brachial index represents a noninvasive, objective way to diagnose peripheral arterial disease. This test has been reported to have a sensitivity above 90% and a specificity of 95% for the diagnosis of peripheral arterial disease.^{9,10} It can be used with versatility in the physician's office.

No potential conflict of interest relevant to this article was reported.

REFERENCES

1. Reich RS. The pulses of the foot: their value in the diagnosis of peripheral circulatory disease. *Ann Surg* 1934;99:613-22.
2. Clain A, ed. *Hamilton Bailey's demonstrations of physical signs in clinical surgery*. 16th ed. Bristol, United Kingdom: John Wright, 1980.
3. Gerhard-Herman M, Gardin JM, Jaff M, Mohler E, Roman M, Naqvi TZ. Guidelines for noninvasive vascular laboratory testing: a report from the American Society of Echocardiography and the Society of Vascular Medicine and Biology. *J Am Soc Echocardiogr* 2006;19:955-72.
4. Rumwell C, McPharlin M. *Vascular technology*. 2nd ed. Pasadena, CA: Davies Publishing, 2000:1-120.
5. White C. Intermittent claudication. *N Engl J Med* 2007;356:1241-50.
6. Hiatt WR. Medical treatment of peripheral arterial disease and claudication. *N Engl J Med* 2001;344:1608-21.
7. Norgren L, Hiatt WR, Dormandy JA, Nehler MR, Harris KA, Fowkes FG. Inter-society consensus for the management of peripheral arterial disease (TASC II). *J Vasc Surg* 2007;45:Suppl S:S5-S67.
8. Hirsch AT, Haskal ZJ, Hertzner NR, et al. ACC/AHA Guidelines for the Management of Patients with Peripheral Arterial Disease (lower extremity, renal, mesenteric, and abdominal aortic): a collaborative report from the American Associations for Vascular Surgery/Society for Vascular Surgery, Society for Cardiovascular Angiography and Interventions, Society for Vascular Medicine and Biology, Society of Interventional Radiology, and the ACC/AHA Task Force on Practice Guidelines (writing committee to develop guidelines for the management of patients with peripheral arterial disease) — summary of recommendations. *J Vasc Interv Radiol* 2006;17:1383-97.
9. Ouriel K, McDonnell AE, Metz CE, Zarins CK. Critical evaluation of stress testing in the diagnosis of peripheral vascular disease. *Surgery* 1982;91:686-93.
10. Yao ST, Hobbs JT, Irvine WT. Ankle systolic pressure measurements in arterial disease affecting the lower extremities. *Br J Surg* 1969;56:676-9.

Copyright © 2009 Massachusetts Medical Society.